

# An iliopsoas abscess differentiated from recurrent colonic cancer without an invasive surgical procedure using US and CT-guided percutaneous aspiration and biopsy

Yoshihiro Moriwaki, Jun Otani, Junzo Okuda, Hitomi Zotani, So Kasuga

**Abstract:** Today, we often encounter iliopsoas abscesses. A 72-year-old male, who had operated for ascending colon cancer and a local recurrence after 2 years and had survived without recurrence for the next 13 years, was pointed a right iliopsoas lesion suspicious abscess or tumor by plane CT, which was suspected such as abscess or recurrent cancer but not simple hematoma on contrast enhanced CT and MRI images. US showed high echoic irregular area with unclear margin and with low echoic heterogeneous coarse internal echo pattern, which indicated a primary or secondary abscess rather than hematoma. We could perform aspiration sampling of material for bacterial culture and core needle biopsy under real time US and CT guidance, resulting in positive culture of few anaerobes and no evidence of neoplastic cell. He has been well without detection of any neoplasm for 2 years. We could obtain useful information from US/CT-guided aspiration and core needle biopsy for differential diagnosis among simple aseptic hematoma, bacterial abscess and neoplastic lesion with/without infection, without great risks and damage for the patients. The surgical approach requires an invasive procedure with hemorrhage, resulting in the possibility of spreading and implanting infectious materials or neoplastic cells.

**Key words:** Iliopsoas abscess, differential diagnosis from local recurrence of the right side colon; US/CT-guided percutaneous aspiration and biopsy

(雲南市立病院医学雑誌 2020; 16(2):47-51)

## INTRODUCTION

Primary iliopsoas abscesses are known as rare conditions requiring appropriate aspiration, drainage and/or invasive surgical procedures for sampling bacteria and antibiotic or invasive anatomical therapy<sup>1)</sup>. The invasive surgical procedure should be avoided using less invasive diagnostic and therapeutic alternatives. Today, we often encounter this pathophysiological feature in the differentiating course of lumbago, lateral abdominal pain and/or fever and chills

using computed tomography (CT)<sup>2)</sup>. This condition should be differentiated from a simple iliopsoas hematoma or tumorous lesion without infection, in which condition we should select therapeutic strategies other than antibiotics. Here, we present a case of a right iliopsoas abscess in a hematoma. We could differentiate the lesion from recurrent colonic cancer using contrast-enhanced CT (CE-CT), magnetic resonance imaging (MRI) and ultrasonography (US). Furthermore, US- and CT-guided percutaneous aspiration and biopsy were performed, and we could avoid

Department of Surgery, Unnan City Hospital [96-1 Daito-cho Iida, Unnan, Shimane 699-1221, JAPAN]

Corresponding author: Yoshihiro Moriwaki, Department of surgery, Unnan City Hospital [96-1 Daito-cho Iida, Unnan, Shimane 699-1221, JAPAN]

Telephone: 0854-47-7500 / Fax: 0854-47-7501

E-mail: yoshimoriwaki@gmail.com

(受付日: 2019年12月1日, 受理日: 2020年3月1日, 印刷日: 2023年6月30日)

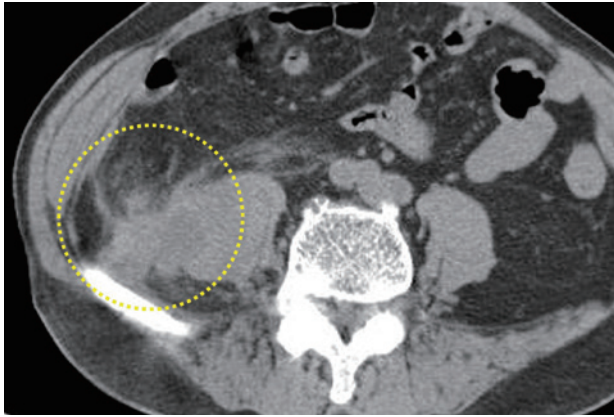


Figure 1: Abdominal CT images at the out-patient department showing a right iliopsoas space occupying lesion (yellow dotted circle)

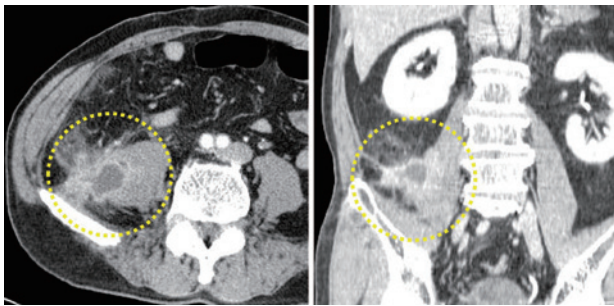


Figure 2: Contrast enhanced CT on the second hospital day showing 54x32x31mm of mass lesion in the right iliopsoas muscle with unclear margin, with central low density area and staining around mass (yellow dotted circles)

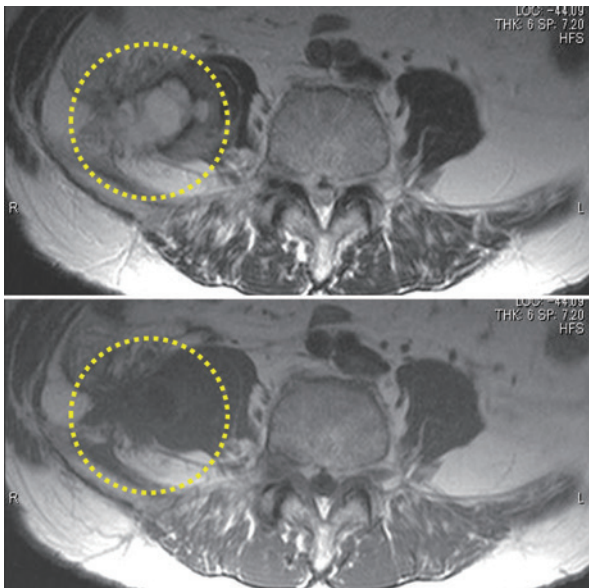


Figure 3: MRI on the second hospital day showing a right iliopsoas mass with central fluid collection with high intensity around mass in T2 images (yellow dotted circles)

performing invasive surgical procedures.

## CASE PRESENTATION

A 72-year-old male Unnan city inhabitant under treatment for hypertension and hyperlipidaemia visited the outpatient department of our hospital out of schedule complaining of cough, sputa and pharyngeal pain for one month and right abdominal and lumbar pain for 4 months without fever. He had undergone curative resection for ascending colon cancer and reoperation for a local recurrence 2 years after the primary operation, after which he survived with a recurrence-free interval for the next 13 years. He presented in good general condition, except for slight right lumbar pain with tapping and a mild inflammatory response in the blood examination, and was told to go back home after plain CT scanning. However, we found a right iliopsoas space-occupying lesion with a suspicious abscess or tumour (Figure 1) and called him back for admission to our hospital.

Contrast-enhanced CT on the second hospital day showed a 54 x 32 x 31 mm mass lesion in the right iliopsoas muscle with an unclear margin adjacent to the previous operative field, with a central low density area and staining around the mass without lymph node swelling around the lesion, which was suspected to be either an abscess or recurrent colon cancer (Figure 2). MRI showed a right iliopsoas mass with central fluid collection with high intensity around the mass in T2 images (Figure 3). Both imaging findings indicated that the lesion was not a simple hematoma. US showed a highly echoic iliopsoas irregular area with unclear margins and a low echoic heterogeneous coarse internal echo pattern attached to the iliac bone, which indicated a primary or secondary abscess rather than a hematoma with aseptic internal melting (Figure 4).

Under real-time US guidance, we punctured the mass to sample the contents for bacterial examination, keeping clear of the 2 detectable sized vessels beside the puncture route to the mass safely and could confirm no vascular injuries during and after the procedure. We obtained slightly thick bloody fluid and started his treatment as a bacterial iliopsoas abscess using meropenem. However, we could not obtain evidence of the existence of bacteria in the thick bloody

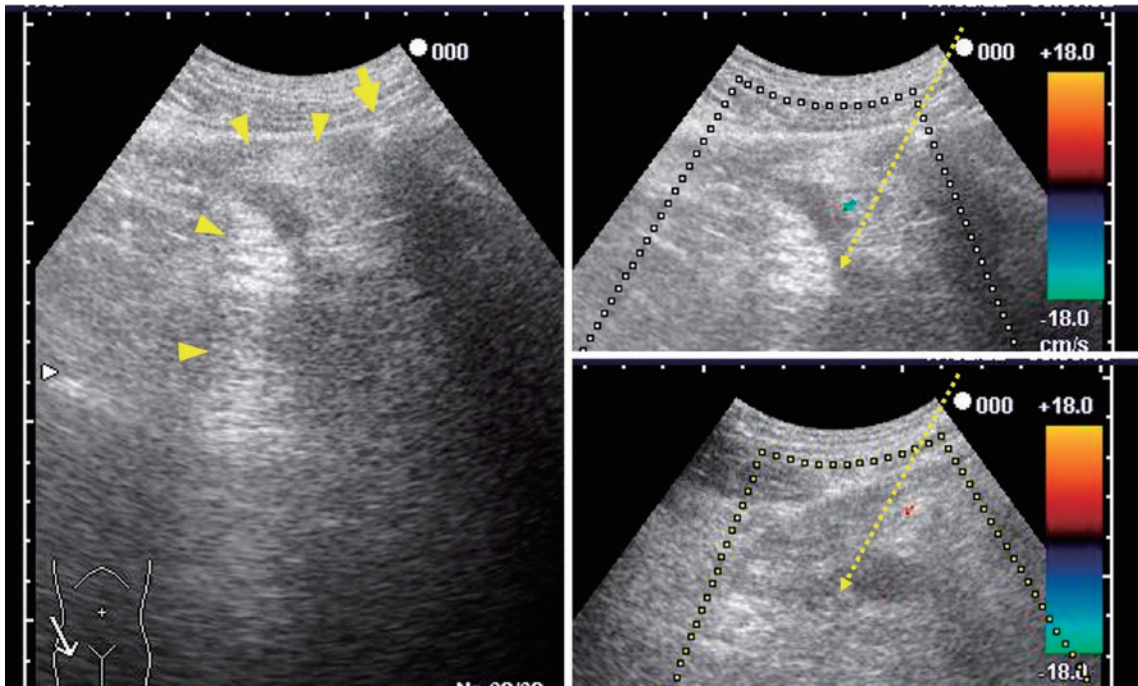


Figure 4: US showing high echoic iliopsoas irregular area with unclear margin and with low echoic heterogeneous coarse internal echo pattern (yellow arrow heads) attached to the iliac bone (yellow arrow)

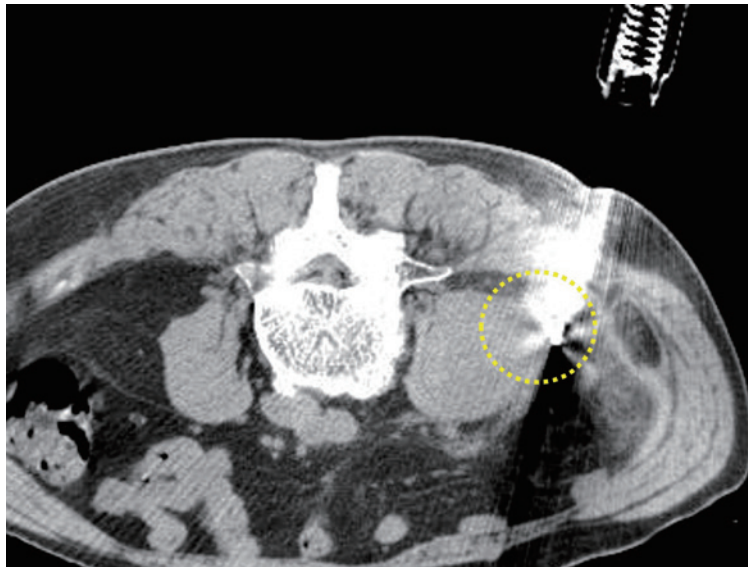


Figure 5: Aspiration sampling of material again and Core needle biopsy (yellow dotted circle) under real time US and CT guidance on the 11th hospital day

fluid obtained from the puncture of the mass. Contrast-enhanced CT on the 9th hospital day showed no increase in the size of the mass after administration of antibiotics. On the 11th hospital day, we performed aspiration sampling of material again and core needle biopsy under real-time

US and CT guidance (Figure 5) , resulting in a positive culture for a few anaerobic Gram negative rods which could not be identified and inflammatory granulation tissue with no evidence of neoplastic cells. He was discharged home on the 22nd hospital day. Although he consulted another

high-volume hospital, he was well without detection of any neoplasm for 2 years.

## DISCUSSION

US-guided percutaneous puncture and/or drainage is thought to be helpful as a supplement to antibiotic therapy for a primary bacterial infectious abscess or bacterial abscess secondary to a tumorous lesion or intramuscular hematoma<sup>3,4)</sup>, even if adequate drainage is difficult. In this case, it was also important to deny the recurrence of the previous cancer to avoid invasive procedures. Although aspiration sampling of the contents and core needle biopsy could not completely deny the existence of bacteria and malignant cells and were not conclusive diagnostic tools, as in this case, we could obtain useful information from these procedures without great risks and damage to the patients compared with surgical procedures.

The surgical approach for iliopsoas lesions<sup>5,6)</sup> usually requires a highly invasive procedure with a large incision and substantial hemorrhage during release of the retroperitoneal space in the ileac pouch, resulting in the possibility of spreading and implanting infectious materials or neoplastic cells.

On the other hand, there are some critical complications in percutaneous aspiration or core needle biopsy, even when using real-time US guidance, such as inadvertent vascular and intestinal injuries. However, under real-time US guidance, gross vascular injuries could be easily avoided. In our case, we avoided injuries of extended vessels around the lesion, appearing as one of the inflammatory responses. Under adequate preparation, leakage from the small pores of the nonextended healthy intestine injured by fine needles used during the aspiration procedure may be very small and will not become the cause of severe peritonitis. It is thought to be safe and appropriate to prepare for the inadvertent occurrence of this adverse event using preparation for colonoscopy, because it is well known that idiopathic perforation during elective colonoscopy is seldom followed by severe peritonitis.

## CONCLUSIONS

US-guided percutaneous puncture and/or biopsy for an

iliopsoas lesion is thought to be less invasive and useful for differential diagnosis among simple aseptic hematoma, bacterial abscess and neoplastic lesion with/without infection.

## References

- 1) Tabrizian P, Nguyen SQ, Greenstein A, et al. Management and treatment of iliopsoas abscess. *Arch Surg.* 2009;144:946-949.
- 2) Ouellette L, Hamati M, Flannigan M, et al. Epidemiology of and risk factors for iliopsoas abscess in a large community-based study. *Am J Emerg Med.* 2019;37:158-159.
- 3) Aboobakar R, Cheddie S, Singh B. Surgical management of psoas abscess in the Human Immunodeficiency Virus era. *Asian J Surg.* 2018;41:131-135.
- 4) Ohara N, Tominaga O, Uchiyama M, et al. Primary iliopsoas abscess successfully treated by ultrasonographically guided percutaneous drainage. *J Orthop Sci.* 1998;3:221-224.
- 5) Tabrizian P, Nguyen SQ, Greenstein A, et al. Management and treatment of iliopsoas abscess. *Arch Surg.* 2009;144:946-949.
- 6) Charalampopoulos A, Macheras A, Charalabopoulos A, et al. Iliopsoas abscesses: diagnostic, aetiologic and therapeutic approach in five patients with a literature review. *Scand J Gastroenterol.* 2009;44:594-599.

## USとCTガイド下の低侵襲の経皮吸引細胞診と針生検で大腸癌局所再発と鑑別し得た腸腰筋膿瘍

森脇 義弘, 大谷 順, 奥田 淳三, 象谷ひとみ, 春日 聡

**要 旨：**腸腰筋膿瘍は比較的遭遇し易い病態である。症例は、72歳男性で、上行結腸癌術後2年で局所再発に対し再発巣切除術が行われた後13年間無再発で経過していた。今回、単純CTで右腸腰筋内に膿瘍や再発を疑わせる像を認め、造影CTやMRIも実施されたが、単純な血管腫ではないと思われたが診断には至らなかった。USでは、不整型で境界不明瞭な高エコー、内部は底エコー領域が混在した像として描出され、血管腫より膿瘍が疑われた。USとCTガイド下に培養検体採取、吸引細胞診と針生検を行い、微量検体から嫌気性菌を培養検出し、悪性腫瘍細胞は採取されなかった。その後2年間癌再発兆候はない。US/CTガイド下吸引細胞診/針生検は、患者への侵襲を押さえながら、無菌性単純血管腫や無菌性血腫、細菌性膿瘍、腫瘍性病変の鑑別に有用な情報を提供する。この部への手術的アプローチは、出血を伴う侵襲的なものとなり、結果的にも感染性物質や腫瘍性物質の散布も懸念される。

**キーワード：**腸腰筋膿瘍, 右側結腸癌局所再発との鑑別, US/CTガイド下経皮的吸引細胞診/針生検

---

雲南市立病院外科

著者連絡先：森脇義弘 雲南市立病院外科〔〒699-1221 島根県雲南市大東町飯田96-1〕

TEL: 0854-47-7500

E-mail: yoshimoriwaki@gmail.com